

# Anatomical Study and Clinical Considerations of Greater Palatine Foramen in Adult Human Skulls of North Indian Population

SUSHOBHANA, SUNITI RAJ MISHRA, SHAIENDRA SINGH, JIGYASA PASSEY, RAHUL SINGH, PRIYANKA SINHA

## ABSTRACT

**Introduction :** The knowledge of position of greater palatine foramen is fundamental in oral surgery interventions because the neurovascular bundle, greater palatine nerve and vessels emerge through it and can be principally assessed here for performing anaesthetic techniques for desensitization of the hard palate or harvesting a gingival mucoperiosteal graft.

**Aim :** The present study was carried out to identify the morphological shape, position and location of greater palatine foramen and the direction of greater palatine foramen in adult human skulls.

**Materials and Methods:** The location of the greater palatine foramen in relation to 3<sup>rd</sup> molar along with shape and direction of the opening on palate was observed in 50 (25 males and 25 females) adult human dry skulls of North

Indian population. The perpendicular distance of GPF from mid-maxillary suture and posterior border of hard palate was also measured on both sides. Measurements were done with vernier caliper.

**Results:** The mean distance of the greater palatine foramen from palatine suture was 13.38 mm while the mean distance from posterior border of hard palate was 3.36 mm. There was no statistically significant difference between male and female skulls as well as right and left sides.

**Conclusion:** It was concluded that the 3<sup>rd</sup> molar can be taken as a reliable landmark for locating greater palatine foramen and in cases of unerupted 3<sup>rd</sup> molar, palatine suture and posterior border of hard palate can be used as standard landmarks for this purpose.

**Keywords:** Dental anaesthesia, Greater palatine canal, Hard palate, Molar teeth

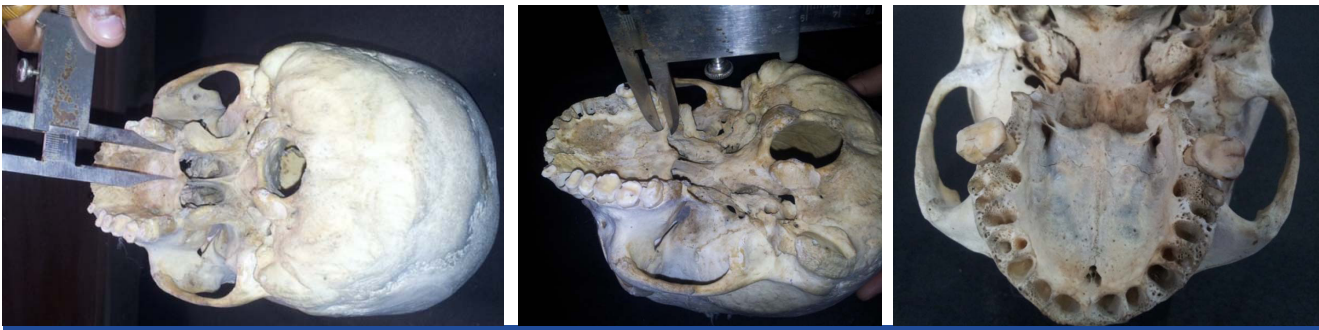
## INTRODUCTION

The greater palatine foramen (GPF) conducts greater palatine nerve and greater palatine vessels. Greater palatine foramen is an important anatomical landmark for dentists and maxillofacial surgeons and plastic surgeons. The foramen is also crucial for being the point of entrance of the palatine canal for reaching the pterygopalatine ganglion [1].

The block anesthesia of the greater palatine nerve which innervates the posterior part of hard palate in the greater palatine foramen (GPF) is largely used in minor oral surgeries, periodontics and general dentistry. Furthermore, the area of the GPF serves as a donor of soft tissue graft [2]. Hard palate grafting is a successful and commonly practiced approach in oculoplasty surgeries for eyelid and socket reconstruction. Vascularization of the mucoperiosteum of the hard palate comes mainly from the greater palatine vessels (branch of

descending palatine artery from the maxillary artery) which emerge from the greater palatine foramen [3,4]. Therefore, while harvesting oral mucoperiosteal graft for reconstructive surgeries for lips and urethra, the knowledge of anatomy of GPF and its variations is important.

For achieving profound anesthesia the exact anatomical location of GPF for nerve block is required. There are varying opinion about the location of the greater palatine foramen among the researchers for example, it is termed to be located near the lateral border of hard palate [5], opposite the last molar [6], in relation to 2<sup>nd</sup> molar [7] or 3<sup>rd</sup> molar [2,8,9], anywhere between the maxillary second and third molars [10,11]. However, there is need for other landmarks for those patients in whom 3<sup>rd</sup> molar remained unerupted. In such patients distance from other bony landmarks like mid maxillary suture and posterior border of hard palate might



**[Table/Fig-1]:** Distance between greater palatine foramen and midline maxillary suture. **[Table/Fig-2]:** Distance between greater palatine foramen and posterior border of hard palate. **[Table/Fig-3]:** Showing bilateral irregular shape of greater palatine foramen medial to 3<sup>rd</sup> Molar with a lingula like projection from lateral wall

prove helpful. Thus, the present study was carried out to study the morphology and topography of the greater palatine foramen in North Indian population.

## MATERIALS AND METHODS

The present study was an anthropometric study conducted during 2014-15, on 50 (25 males and 25 females) adult human dry skulls of North Indian population to determine the location of greater palatine foramen in maxilla. The sample skulls were collected from Anthropology museum, Department of Anatomy, G.S.V.M. Medical College, Kanpur. The skulls of known sex with no apparent deformity or diseases, homogenous in the form of maxillary arches, dentulous or partially edentulous having full eruption of upper third molar, without malposition of teeth, were included in the study while the senile skulls with alveolar bone resorption and juvenile skulls were excluded from the study. The plan of the study was as follows-

### A. As the first step of study, Non Metric Parameters were observed in terms of-

- Shape of the greater palatine foramen – It was recorded as oval, round or irregular
- Location of the foramen in relation to maxillary molar teeth.
- Direction of opening of greater palatine foramen on palate: For determining the direction of opening of the foramen on the palate, a needle was inserted into the GPF. The directions were recorded as: antero-medial, anterior and anterolateral.
- Besides GPF, the presence and number of lesser palatine foramen were also observed and recorded

### B. Now, the well defined metric parameters were selected. The anatomical landmarks used in the present study were:-

- Perpendicular distance from the medial wall of the GPF to the midline maxillary suture (MMS) (PM distance) [Table/Fig-1].
- Distance from the posterior wall of the GPF to the

posterior border of the hard palate (PBHP) [Table/Fig-2].

All observations were recorded separately for male and female skulls. All measurements were done bilaterally and directly on the dry skulls, performed with a stainless steel metric Vernier caliper with 0.1mm precision. All the measurements were taken very carefully and done by single observer to avoid any inter-observer error.

### C. Data management and statistical analysis

The non-metric parameters were recorded on both sides in 50 skulls and the conclusion was derived in toto for 100 cases. All the metric parameters, recorded on both sides, were statistically analyzed. Student's 't' test was performed. Mean and standard deviation were calculated for the ranges of each parameter. A p-value was determined to assess the significance of the observations.

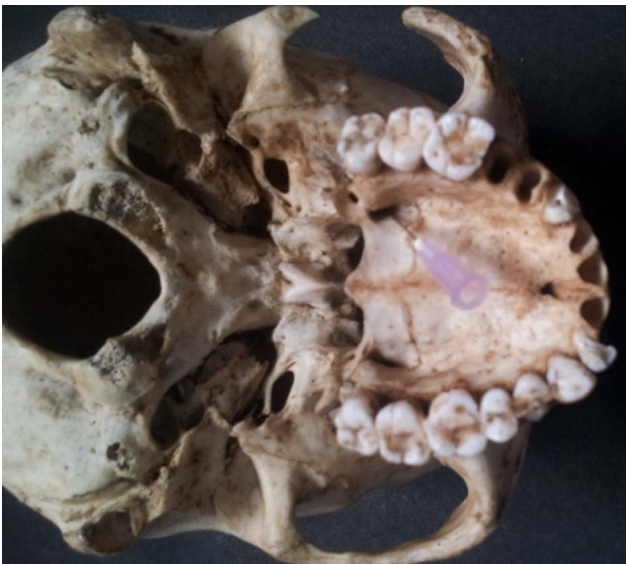In the study, sexual dimorphism was not evident on gross examination for any non metric parameters yet the metric parameters were further tabulated according to sex and subjected to statistical analysis to confirm sexual dimorphism, if any.

## RESULTS

The shape of greater palatine foramen was oval in anteroposterior direction in 74% of cases while it was round in 23 % and irregular in 3% [Table/Fig-3]. In the irregular foramina the lingula like projection as seen in mandibular foramen was present projecting from postero-lateral border of the greater palatine foramen.

As regards the relation of greater palatine foramen with maxillary molar it was found that in 14 percent of cases greater palatine foramen was located opposite 2<sup>nd</sup> maxillary molar tooth, 10 percent cases it was between 2<sup>nd</sup> and 3<sup>rd</sup> molar tooth while 76 percent cases had greater palatine foramen opposite 3<sup>rd</sup> molar. This relation was identical on both sides.

The opening of greater palatine foramen on the palate on both sides was directed anteromedially in 72 percent of cases



**[Table/Fig-4]:** Location of greater palatine foramen medial to 3<sup>rd</sup> molar and its opening in anteromedial direction on palate

A	Shape of the greater Palatine Foramen	Right side (n = 50)	Left side (n = 50)	Total (n = 100)
1	Oval (Antero-Posteriorly)	37	37	74
2	Round	11	12	23
3	Irregular	2	1	3
B Relation with Maxillary molar				
1.	2 <sup>nd</sup> molar	7	7	14
2.	2 <sup>nd</sup> /3 <sup>rd</sup> molar	5	5	10
3.	3 <sup>rd</sup> molar	38	38	76
C Direction of opening of foramen onto the palate				
1.	Antero-medial	34	38	72
2.	Anterior	8	9	17
3.	Antero-lateral	8	3	11
D Presence of Lesser Palatine Foramen (LPF)				
1	Skulls with no LPF	2	0	2
2	One LPF	24	19	43
3	Two LPF	17	23	40
4	Three LPF	7	8	15

**[Table/Fig-5]:** Showing observations regarding non-Metric Parameters A) Shape of GPF B) Relation of GPF to maxillary molar and C) the direction of opening of GPF on the palate and D) Presence of LPF on both sides

[Table/fig-4]. It was directed anteriorly in 17 percent while directed anterolaterally in 11 percent of cases [Table/fig-5].

Lesser palatine foramen was present in all skulls except 2 skulls which had no lesser palatine foramina on right side. The single or double lesser palatine foramen was seen in 43% and 40% cases respectively. The mean distance of greater palatine foramen (GPF) to midline maxillary suture (MMS)

S. No	Observations and Statistical analysis	Distance of greater palatine foramen to midline maxillary suture		Distance of greater palatine foramen to posterior border of hard palate	
		Right (mm)	Left (mm)	Right (mm)	Left (mm)
1.	Range	10-16	11-15	1-7	1-7
2.	Mean (mm) ±SD	13.38± 1.38	13.58± 1.21	3.38± 1.30	3.34± 1.25
3.	Mode	14	14	3	3
4.	t-value	0.77		0.15	
5.	p-value	p>0.05		p>0.05	

**[Table/Fig-6]:** Showing observations regarding Distance of greater palatine foramen to A) midline maxillary suture and B) posterior border of hard palate

Parameter	Distance of greater palatine foramen to midline maxillary suture		Distance of greater palatine foramen to posterior border of hard palate	
	Right (mm)	Left (mm)	Right (mm)	Left (mm)
Male (Mean± SD)	13.7 ± 1.31	13.4 ± 1.35	3.44 ± 1.44	3.28 ± 1.33
Female (Mean± SD)	12.92 ± 1.58	13.32 ± 1.40	3.44 ± 1.23	3.4 ± 1.3
t-Value	2.0	0.20	Not Calculable	0.32
p-value	<0.05	>0.05	-----	>0.05
Inference	Just Significant	Non Significant	-----	Non Significant

**[Table/Fig-7]:** Showing t-test values in male and female skulls

was 13.38 mm with standard deviation of 1.38 on right side and 13.58 mm with standard deviation of 1.21 on left side. The mean distance of greater palatine foramen to posterior border of hard palate (PBHP) was 3.38 mm with a standard deviation of 1.30 on right side and 3.34 mm on left side with a standard deviation of 1.25. On applying student t-test no significant difference was observed in the values of distance from greater palatine foramen (GPF) to Midline maxillary suture (MMS) and posterior border of hard palate on right and left side as p>0.05 [Table/fig-6]

On gross observations for non-metric parameters there was no disposition of any difference in male and female skulls. The mean values of metric data in the female skulls were lower than those in the male skulls but on statistical evaluation of the observations for male and female skulls on both sides no significant difference was inferred in general except for the distance of GPF from mid maxillary suture on right side which was just significant [Table/Fig-7].

## DISCUSSION

The landmarks used in the present study for localizing the GPF are easily accessible in a patient. In the study, the shape of the GPF was oval, elongated in anteroposterior direction, in 74 %

cases while round in 23% cases and irregular in 3% cases. There was a lingular projection emerging from the Postero-lateral border in the irregular foramina (3%). The presence of such projections might be responsible for the possible obstruction and difficulty in passage of needle while injecting the drug. Such a bony lingular projection, emerging from the posterior border, has also been reported in past [9].

There has been a varying opinion about the position of GPF in relation to the molar tooth. In a study it was observed that the most frequent greater palatine foramen location was between the second and third molars [12] and similar results were observed in studies conducted on Chinese skulls [13]. The most common position in relation to the maxillary third molar was reported in East Indian, Negroid, Nigerian, Iraqi and Indian, Brazilian Kenyan skulls [14-21]. In the present study as well 76% of greater palatine foramen observed, were located opposite 3<sup>rd</sup> molar tooth which was similar to the studies conducted in past specially in Indian skulls [Table/Fig-8].

Researchers	Population studied	Opposite 2 <sup>nd</sup> molar	Between 2 <sup>nd</sup> and 3 <sup>rd</sup> molar	Opposite 3 <sup>rd</sup> molar	Distal to 3 <sup>rd</sup> molar
Wang et al (1988)[13]	Chinese	17	48.50	33.50	0.00
Ajmani (1994)[15]	Nigerian	13.07	38.46	48.46	0.00
Ajmani (1994) [15]	Indian	0.00	32.35	64.69	2.94
Jaffar & Hamadah (2003) [18]	Iraqi	12	19	55	14
Vinay K V et al., (2012) [19]	South Indian	3.67	19	76	1.33
Chrcanovic & Custodio (2010) [20]	Brazilian	0.00	6.19	54.87	38.94
Present Study	North Indian	14	10	76	0

**[Table/Fig-8]:** Showing percentage of position of greater palatine foramen in relation to maxillary molar

The direction of the greater palatine canal is important while probing the GPF to deliver injections. The opening of greater palatine foramen on the palate on both sides was directed anteromedially in 72 percent of cases. It was directed anteriorly in 17 % while directed anterolaterally in 11% of cases. Previous researchers [4,18,21] also found it to be directed anteromedially most commonly. Wang et al., [13] who studied Chinese skulls found the opening directed anteriorly in 90.5% skulls while vertically in 9.5% of skulls. This variation may explain the occasional difficulty encountered while attempting to insert the point of needle into the GPF and

Researchers	Population studied	Antero-lateral	Anterior	Antero-medial	Vertical
Wang et al., (1988) [13]	Chinese	-----	90.5	-----	9.5
Ajmani (1994)[15]	Nigerian	38.5	-----	58.5	3
Ajmani (1994)[15]	Indian	NA	NA	91.1	NA
Jaffar & Hamadah (2003)[18]	Iraqi	-----	36.0	60.0	4.0
Vinay K V et al., (2012) [19]	South Indian	11.67	41.66	43	3.67
Chrcanovic & Custodio (2010) [20]	Brazilian	0.00	69.38	18.75	11.87
Present Study	North Indian	11	17	72	-----

**[Table/Fig-9]:** Comparison of past studies with the direction of greater palatine foramen (Data in Percentage)

pterygopalatine canal [22]. The difference in incidence can be because of racial variations [Table/Fig-9].

The number of LPF varied from one to three or even null in 2 skulls on right sides. In past studies two to five LPF in 40% of skulls [21] while 1 lesser palatine foramen in 62.5% of the skulls [23] and no LPF in 4% of skulls [18] were reported. In cases where no lesser palatine foramina were present it is proposed that lesser palatine nerve and vessels might also be emerging from greater palatine foramen [18].

In the present study, it was observed that the mean distance of greater palatine foramen to palatine suture is 13.38 mm on right side and 13.58 mm on left side. The findings are lesser than that measured by other researchers who conducted study in Chinese [13], Nigerian [15], Iraqi [18] and found it to be between 15 mm-16mm. However, in studies conducted in South Indian skulls [15,19] it was approx 14.6 mm thus lesser than Chinese and Nigerian skulls. Variability in location of the foramen may be due to sutural growth occurring between the maxilla and the palatine bone. The anteroposterior dimension of the palate increases with the eruption of the posterior teeth [22]. The present study was conducted in the skulls of North Indian origin Thus the difference can be attributed to racial and ethnic factors. However, symmetry between right and Left sides was established in all studies.

There was no significant difference seen in the distance from greater palatine foramen (GPF) to posterior border of hard palate (PBHP) on right and left side as  $p > 0.05$ . This finding is comparable to other researchers [15,19-20] who found it 3.39 to 3.58 mm. However, symmetry between right and left sides was established in all studies [Table/Fig-10].

Researcher	Population studied	Distance between GPF to MMS (right side)	Distance between GPF to MMS (left side)	Distance between GPF to PBHP (right side)	Distance between GPF to PBHP (left side)
Wang et al., (1988) [13]	Chinese	16	16	#4.11	
Ajmani (1994) [15]	Nigerian	15.4*		#3.5	
Ajmani (1994) [15]	Indian	14.7	14.6	#3.7	
Jaffar & Hamadah (2003) [18]	Iraqi	15.7*		#4.86	
Vinay K V et al., (2012) [19]	South Indian	14.8	14.8	3.56	3.58
Chrcanovic and Custodio (2010) [20]	Brazilian	14.68	14.44	#3.39	
Present Study	North Indian	13.38	13.58	3.38	3.34

**[Table/Fig-10]:** Comparison between various parameters in present and other studies

\*no distinction between right and left sides

# mean of both sides

Thus, as evident from the present and past studies ethnic variations about the greater palatine foramen have been found and the bilateral symmetry of greater palatine foramen on both sides of each skull is remarkable [4].

On comparing the data for male and female skulls separately it was seen that mean values of male skulls were higher than female skulls as also been reported in past [1]. This can be explained that male skulls, in general are more angled, larger, heavier and they have a higher thickness in skull bones [24]. However, on statistical analysis the difference was not significant except for the distance between GPF and MMS on right side which came out to be just significant.

In view of the substantial importance of the exact location of the greater palatine foramen, the results of this study will be helpful in describing variations of the position of the greater palatine foramen. Besides performing anaesthetic procedures during dental surgeries, the knowledge of greater palatine foramen is also necessary for selecting the area of palatal mucosa graft while harvesting sub epithelial connective tissue grafts (SCTG) from palate since the size of the graft that can be harvested is dictated by the position of the greater palatine neurovascular bundle.

Since, the study was conducted on adult skulls while senile and juvenile skulls were excluded therefore, application of these findings in children for example, while performing primary cleft palate surgery is limited and should be studied further in future.

## CONCLUSION

From the present study it was concluded that the third molar whenever erupted, could be used as a landmark for localizing the greater palatine foramen for successful greater palatine nerve block anesthesia while performing maxillary surgeries and reconstructive surgeries but the parameter has a limitation that due to any periodontal disease or impaction, the presence of third molar tooth in all patients is altogether questionable.

Therefore, in such cases the metric parameters: the mean distance of greater palatine foramen from the midline maxillary suture (palatine suture) and posterior border of hard palate can prove a reliable tool for localizing the greater palatine foramen. The foramen exhibits bilateral symmetry and usually directed anteromedially on the palate in North Indian population. The study will also be useful for localizing greater palatine artery while harvesting a palatal graft for reconstructive surgeries. The palatal mucosa graft around the third molar should be harvested with great caution to prevent damage to the GPF neurovascular bundle.

## ACKNOWLEDGEMENT

We are thankful to the care taker staff of Anthropology Museum at Department of Anatomy, GSVM Medical College, Kanpur.

## REFERENCES

- [1] Teixeira, CS., Souza, VR., Marques, CP., Silva Junior, W. and Pereira, KF. Topography of the greater palatine foramen in macerated skulls *J. Morphol. Sci.* 2010 ; 27( 2): 88-92.
- [2] Ikuta CR, Cardoso CL, Ferreira-Júnior O, Lauris JR, Souza PH, Rubira-Bullen IR. Position of the greater palatine foramen: an anatomical study through cone beam computed tomography images. *Surg Radiol Anat.* 2013;35(9):837-42.
- [3] Gauthier J, Lézy P, Vacher C. Vascularization of the palate in maxillary osteotomies: anatomical study. *Surgical and Radiologic Anatomy.* 2002; 24(1): 13-17.
- [4] Siebert JW, Angrigiani C, McCarthy JG, Longaker MT. Blood supply of the Le Fort I maxillary segment: an anatomic study," *Plastic and Reconstructive Surgery*, 1997;100 ( 4): 843-50.
- [5] Gardner E, Gray DJ, Rahilly O R *Anatomy: a regional study of human structure*, 1975 4<sup>th</sup> edn. WB Saunders, Philadelphia, pp 997.
- [6] Romanes GJ Cunningham. Textbook of Anatomy. 1981, 12<sup>th</sup> edn. *Oxford University Press, New York*, pp 166.
- [7] Selden HM *Practical anesthesia for dental and oral surgery*, 1948, 3<sup>rd</sup> edn. *Lea Fabiger, Philadelphia*, 206.
- [8] Westmoreland EE, Blanton PL. An analysis of the variations in position of the greater palatine foramen in the adult human skull. *Anat Rec.* 1982;204(4):383-88.

- [9] Bruno R. Chrcanovic and Antônio LN. Custódio Anatomical variation in the position of the greater palatine foramen. *Journal of Oral Science*. 2010; 52 (1): 109-13.
- [10] Monheim LM: Local anaesthesia and pain control in dental practice, 1969, 4<sup>th</sup> ed. Mosby, *Saint Louis*, pp 95
- [11] Shane SME. Principles of sedation, local and general anesthesia in dentistry, 1975 1<sup>st</sup> ed. *Charles C Thomas, Illinois*, pp 173.
- [12] Fu JH, Hasso DG, Yeh CY, Leong DJM, Chan HL, Wang HL. The accuracy of identifying the greater palatine neurovascular bundle: a cadaver study. *Journal of Periodontology*. 2011; 82 (7): 1000-06.
- [13] Wang TM, Kuo KJ, Shih C, Ho LL, Liu JC. Assessment of the relative locations of the greater palatine foramen in adult Chinese skulls. *Acta Anatomica*. 1988;132(3): 182-86.
- [14] Westmoreland EE, Blanton PL . An analysis of the variations in position of the greater palatine foramen in the adult human skull. *Anat Rec*. 1982, 204, 383-88.
- [15] Ajmani ML. Anatomical variation in position of the greater palatine foramen in the adult human skull. *Journal of Anatomy*. 1994; 184 (3): 635-37.
- [16] Hassanali J, Mwaniki D . Palatal analysis and osteology of the hard palate of the Kenyan African skulls. *Anat Rec*. 1984; 209: 273-80.
- [17] Langenegger JJ, Lownie JF, Cleaton-Jones PE. The relationship of the greater palatine foramen to the molar teeth and pterygoid hamulus in human skulls. *J Dent*. 1983; 11: 249-56.
- [18] Jaffar AA and Hamadah HJ. An analysis of the position of the greater palatine foramen. *J Basic Med Sc*. 2003; 3 (1):24-32.
- [19] Vinay KV, Beena DN and Vishal K. Morphometric analysis of the greater palatine foramen in south Indian adult skulls. *International Journal of Basic and Applied Medical Sciences*. 2012; 2(3):5-8.
- [20] Chrcanovic R, Custódio ALN. Anatomical variation in the position of the greater palatine foramen, *Journal of oral science* 2010; 52(1): 109-13.
- [21] Hassanali J Mowniki D Palatal analysis and osteology of the hard palate of the Kenyan African skulls. *Anat Rec*. 1984;209: 273-80.
- [22] Slavkin HC, Canter MR, Canter SR An anatomic study of the pterygomaxillary region in the craniums of infants and children. *Oral Surg Oral Med Oral Pathol*. 1996; 21: 225-35.
- [23] D'Souza AS, Mamatha H, Jyothi N. Morphometric analysis of hard palate in south Indian skulls. *Biomedical Research*. 2012; 23 (2): 173-75.
- [24] Pereira CB. and Alvin MCM. Manual para estudos craniométricos e cranioscópicos. Santa Maria: Editora da Universidade Federal de Santa Maria, 1972.

**AUTHOR(S):**

1. Dr. Sushobhana
2. Dr. Suniti Raj Mishra
3. Dr. Shailendra Singh
4. Dr. Jigyasa Passey
5. Dr. Rahul Singh
6. Dr. Priyanka Sinha

**PARTICULARS OF CONTRIBUTORS:**

1. Postgraduate Resident, Department of Anatomy, G.S.V.M. Medical College, Kanpur, Uttar Pradesh, India.
2. Professor and Head, Department of Anatomy, G.S.V.M. Medical College, Kanpur, Uttar Pradesh, India.
3. Lecturer, Department of Anatomy, G.S.V.M. Medical College, Kanpur, Uttar Pradesh, India.
4. Postgraduate Resident, Department of Anatomy, G.S.V.M. Medical College, Kanpur, Uttar Pradesh, India.

5. Postgraduate Resident, Department of Anatomy, G.S.V.M. Medical College, Kanpur, Uttar Pradesh, India.
6. Postgraduate Resident, Department of Anatomy, G.S.V.M. Medical College, Kanpur, Uttar Pradesh, India.

**NAME, ADDRESS, E-MAIL ID OF THE CORRESPONDING AUTHOR:**

Dr. Suniti Raj Mishra  
 Professor and Head, Department of Anatomy,  
 G.S.V.M. Medical College, Kanpur  
 Uttar Pradesh, India  
 E-mail: dr.suniti@yahoo.co.in

**FINANCIAL OR OTHER COMPETING INTERESTS:**

None.

Date of Publishing: **Oct 01, 2015**